

(60)

Application of autologous cultivated corneal epithelium for corneal limbal stem cell insufficiency – short-term results

Zastosowanie hodowli autologicznego nabłonka rogówki w leczeniu niewydolności rąbka rogówki – obserwacje krótkoterminowe

Dobrowolski Dariusz^{1,2}, Wylegała Edward¹, Orzechowska-Wylęgała Bogusława³, Wowra Bogumił¹, Wróblewska-Czajka Ewa¹

¹ Department of Ophthalmology, District Railway Hospital, Katowice, Poland
Head: Professor Edward Wylegała, MD, PhD

² Department of Ophthalmology, St. Barbara Hospital, Sosnowiec, Poland
Head: Dariusz Dobrowolski, MD, PhD

³ Department of Cranio-Facial Surgery, Clinical Hospital, Silesian Medical University, Katowice, Poland
Head: Professor Maciej Misiołek, MD, PhD

Summary:

Purpose: To present results of ocular surface reconstruction with application of cultured corneal epithelium in limbal stem cell insufficiency.

Material and methods: 25 patients suffered from limbal insufficiency in one eye after a chemical or thermal burn. Their healthy eyes were the source of limbal epithelium for corneal epithelial culture. Limbal cells from a 2 mm² biopsy were seeded on amniotic membrane. Cultures were carried out in standard conditions in supplemented DMEM in presence of 3T3 fibroblasts. After superficial keratectomy the amniotic carriers with epithelial cells were transplanted on denuded corneas. The presence of corneal vascularization, epithelial regularity and visual acuity were evaluated.

Results: Postoperative follow-up ranged from 3 up to 9 months, average 4.9 ± 1.1 months. 3 months after the surgery 72.0% of the eyes showed stable epithelium with slight corneal haze caused by the amnion. In 60.0% of the eyes there was no recurrent conjunctival neovascularization. 28.0% of the eyes remained cloudy due to stromal revascularization. In 2 eyes total conjunctival pannus developed again. Visual acuity ranged from counting fingers to 0.6.

Conclusion: Transplantation of cultured epithelium is a promising method in treatment of limbal stem cell insufficiency giving satisfactory restoration of corneal epithelium.

Key words:

Cornea, cultivated epithelium transplantation, limbal insufficiency.

Streszczenie:

Cel: przedstawienie wyników rekonstrukcji powierzchni oka z zastosowaniem hodowli nabłonka rogówki u pacjentów z niewydolnością rąbka rogówki.

Materiał i metody: analizowano 25 pacjentów z nabytą niewydolnością rąbka rogówki jednego oka w wyniku oparzeń chemicznych lub termicznych. Drugie oko – zdrowe – było źródłem nabłonka rąbkowego. Komórki pobrane z 2 mm² biopsji rąbka wysiewano na podłoże z błony owodniowej. Hodowle prowadzono w standardowych warunkach we wzbogaconym medium DMEM/HAM F12 w obecności warstwy fibroblastów. W oku biorcy po powierzchniowej keratektomii podłoże owodniowe wraz z hodowanymi komórkami umieszczano na odsłoniętej rogówce. Oceniano obecność unaczynienia rogówki, ciągłość nabłonka i ostrość wzroku badanych.

Wyniki: obserwacja pozabiegowa wynosiła od 3 do 9 miesięcy, średnio $4,9 \pm 1,1$ miesiąca. Trzy miesiące po zabiegu 72,0% oczu wykazywało stabilność nabłonka z widocznym przymgleniem zrębu spowodowanym owodnią. W 60,0% oczu nie obserwowano ponownej rewaskularyzacji spojówkowej. 28,0% rogówek pozostało zmętniałych z obecną waskularyzacją zrębu rogówki. Dwoje oczu rozwinęło ponownie całkowitą łuszczkę spojówkową. Ostrość wzroku wahała się od liczenia palców do 0,6.

Wnioski: przeszczep nabłonka rogówkowego pochodzącego z hodowli stanowi obiecującą metodę leczenia niewydolności rąbkowych komórek macierzystych, która daje zadowalający rezultat w postaci odtworzonego nabłonka rogówkowego.

Słowa kluczowe:

rogówka, przeszczep nabłonka z hodowli, niewydolność rąbka.

Limbal stem cell deficiency is a challenging condition, which requires complex surgical management based on understanding the anatomical and pathophysiological background of the disease. Lack of the corneal epithelium leads to a secondary

pathologic process – covering denuded cornea by conjunctival epithelium. This condition is called limbal stem cell deficiency (LSCD). Cornea is cloudy with persistent epithelial defects or irregular epithelium, develops conjunctival vascularization ac-

Grade/ Stopień	Prognosis/ Rokowanie	Cornea/ Rogówka	Conjunctiva/ Limbus/ Spojówka/ Rąbek
I	Good	Corneal epithelial damage	No limbal ischaemia
II	Good	Corneal haze, iris details visible	<1/3 limbal ischaemia
III	Guarded	Total epithelial loss, stromal haze, iris details obscured	1/3–1/2 limbal ischaemia
IV	Poor	Cornea opaque, iris and pupil not visible	>1/2 limbal ischaemia

Tab. I. Severity of ocular burns by Roper-Hall.

Tab. I. Ciężkość oparzeń powierzchni oka wg skali Ropera-Halla.

Grade/ Stopień	Prognosis/ Rokowanie	Limbal involvement/ Zajęcie rąbka	Conjunctival involvement/ Zajęcie spojówki
I	Very good	0 clock hours	0%
II	Good	<3 clock hours	<30%
III	Good	>3–6 clock hours	>30–50%
IV	Good to guarded	>6–9 clock hours	>50–75%
V	Guarded to poor	>9–<12 clock hours	>75–<100%
VI	Very poor	Total limbus involved	Total conjunctiva involved

Tab. II. Severity of ocular burns by Dua.

Tab. II. Ciężkość oparzeń powierzchni oka wg skali Dua.

accompanied by inflammatory infiltration. Vision is blurred, a patient's ocular discomfort increases. The disease has progressive follow up leading to corneal cicatrization and loss of its transparency (1).

Ocular burns, iatrogenic lesions, infections cause damage to the limbal barrier between corneal and conjunctiva followed by invasion of the conjunctival epithelium and vessels. Coexisting inflammation leads to progressing destruction of cellular architecture on the corneal surface. In many cases superficial changes do not interfere with the visual axis when they are in a peripheral location, however the conjunctival pannus covering corneal center causes progressive loss of visual acuity and mild to severe discomfort. Loss of Vogt palisades, corneal epithelial haze, neovascularization is observed early, severity is strongly dependent on a number of clock hours of effected tissues. Depth of the changes, involvement of the stroma and conjunctiva are also very important for further surgical management and the final prognosis. Involving the corneal stroma makes the pathology more difficult to manage with (2). Severity of alkali and acid burns depends on the type and concentration of the burning agent. Acids coagulate proteins and cause superficial barrier for further penetration. Alkali burns are commonly considered the most dangerous ones due to their hydrophilic and lipophilic features. Good penetration and necrosis of tissues cause severe outer and inner ocular lesions (3).

Success depends on good qualification, therefore we look for the best ocular surface description model. Proper evaluation of ocular surface lesions can help in efficient qualification for surgery. There have been several attempts to describe ocular surface involvement in limbal stem cell deficiency. Majority of patients suffered from ocular burns therefore the scales describe severity of the surface lesions including treatment suggestions and the final prognosis. In spite of it, these methods

are universal. Severity of the disease and location of the superficial changes can be evaluated in both, congenital and acquired disorders.

The oldest scale proposed focusing on the general ocular surface status (4). Another one proposed by Dua focuses on particular tissue involvement in the pathology (5). Scales are described in Tables I and II. Nowadays the Dua scale seems to be more accurate in describing ocular surface disorders. The concept of epithelial culture is to exchange conjunctival epithelium with cultured corneal epithelial cells. The idea of the surgery is to be superficial and minimally invasive. The Dua scale goes forward, he analyses corneal and conjunctival involvement – the tissues interfering with each other on the ocular surface. This concept meets the concept of cultured corneal epithelium surgery. The main purpose is to restore anatomic location of both epithelia. The Dua scale describes them both in ocular pathology and gives a better look at the expected results.

The authors planning a surgery evaluated ocular surface involvement with Dua scale, other changes were also embedded in inclusion/exclusion criteria.

Aim

To describe clinical outcomes of autologous cultivated epithelium transplantations on corneal surface restoration.

Material and methods

The patients with a single eye limbal stem cell deficiency were qualified as limbal epithelium autologous donors. All the patients suffered from ocular burns (chemical or thermal). Inclusion criteria of local corneal involvement were: presence of conjunctival pannus, none or minimal stromal vascularization, present conjunctival inferior and superior fornix, stable corneal surface after the burn. We excluded patients with deep stromal

vessels, cicatrized conjunctiva, synblepharon, a severe dry eye. Severity of the burns was evaluated according to Harminder Dua scale, patients with grades from IV to VI were qualified for the surgery. Culture transfer carrier was denuded amniotic membrane, cultures were carried in presence of feeder layer of 3T3 fibroblasts. Details of the culture procedure are described in the previous paper.

In brief: limbal stem cells were collected as a limbal 2 mm² biopsy from the superior limbus in the operating theatre under local anesthesia. Tissue was transferred to corneal storage medium at 4 degrees Celsius and immediately after donation sent to the laboratory. The tissue specimen was trypsinised to obtain cell suspension with 1% trypsin with 0.01% EDTA for 10 mins. Single cells were seeded on denuded amniotic membrane. Amniotic membrane slides are provided by Homograft Tissue Bank in Zabrze. The amniotic membrane samples are washed out from crioprotective medium in hot Phosphate Buffered Saline (PBS), the amniotic epithelium is gently scraped with culture scraper. Then an amniotic membrane sheet is placed over inactivated with Mitomycin C 3T3 fibroblasts. Cultures were carried out in standard conditions (in temperature of 37°C in humidified atmosphere of 5% CO₂ and 95% air) in supplemented DMEM/HAM F12 medium. Culture medium was changed every 48 hours. After 2 weeks the cultures were qualified for grafting. Histologic examination and immunostaining for cytokeratins 3, 12, 19, connexin 43, protein p63 were performed to confirm the corneal epithelium origin and its proliferative potential.

Surgical procedure

Patients were operated under topical anesthesia. A 360 degree peritomy was performed to establish graft margins. Conjunctiva was settled at 1-2 mm behind the limbal area with 10-0 nylon sutures. Then conjunctival pannus was gently removed with a spatula or a crescent knife. In the eyes with stromal vascularization a superficial keratectomy to remove scarred tissue was performed. Amniotic carriers with epithelial cells were transplanted on denuded corneas. Peripheral continuous 10-0 nylon suture was applied to stabilize the graft. Bandage contact lens was put on the corneal surface at the end of surgery. All the procedures were performed by one surgeon (DD). Postoperative pharmacotherapy was only topical. Ofloxacin and dexamethason eye-drops were administered 5 times a day in the postoperative 2 weeks period. Than only dexamethason was applied 3 times a day for another 6 weeks. Stabilization of corneal surface was analyzed with topical fluorescein staining. Regular epithelium without defects was qualified as a stable corneal surface. No conjunctival vessels and maintained integrity of transplanted epithelium were considered as successful cases. Irregular vascular network in the limbus was characteristic for a cultivated corneal epithelial transplant despite the cases where the vessels tended to grow towards the corneal center.

25 patients were donors and recipients of limbal epithelium for corneal epithelial culture in the study. There were 23 men and 2 women. The recipients' age ranged from 13 to 73 years, the average was 38.7 ± 16.1 years. Each of the patients suffered from limbal stem cell deficiency in one eye with total or partial conjunctival pannus, the fellow eye was healthy. Visual acuity ranged from hand movements to 0.2.

Results

3 months after the surgery 72.0% of the eyes showed stable epithelium with slight corneal haze caused by the amnion. These corneas were not stained by fluorescein solution. The subepithelial haze was disappearing slowly in the following weeks however in 7 patients amniotic margins were clearly visible at the end of the 3 months period. 28.0% of the patients suffered from different epithelial defects from single local defects to large areas of denuded cornea, finally these eyes developed stromal scarring, conjunctival or stromal vascularization.

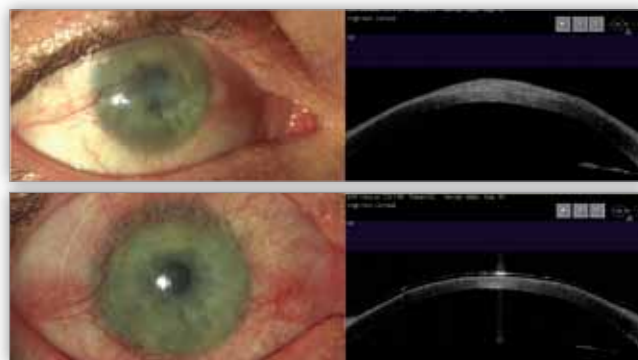


Fig. 1. Preoperative condition with thick conjunctival pannus on upper photograph and OCT. Below the same eye after surgery.

Ryc. 1. Stan przed zabiegiem operacyjnym z grubą łuszczyką spojówkową na górnej fotografii oraz skanie OCT. Poniżej to samo oko po zabiegu.

In 60.0% of the eyes there was no recurrent conjunctival neovascularization. In 3 eyes we observed local conjunctival vascular ingrowth successfully treated with gentle removal of conjunctival tissue with a crescent knife. In majority of the patients (14 eyes, 56.0%) the limbal area was irregular with a number of vessels in the limbal region. There was no tendency to spread these vascular abnormalities towards the central cornea. It was considered that with cultured epithelium transplantation we are unable to restore regular limbal margins. We decided to qualify the eyes as a graft failure in case of superficial revascularization of the corneal centre and stromal scarring with new stromal vessels. 28.0% of the eyes remained cloudy due to stromal revascularization and met graft failure criteria. In 2 eyes total conjunctival pannus developed again. Visual acuity 3 months after the surgery ranged from counting fingers to 0.6 (Tab. III).

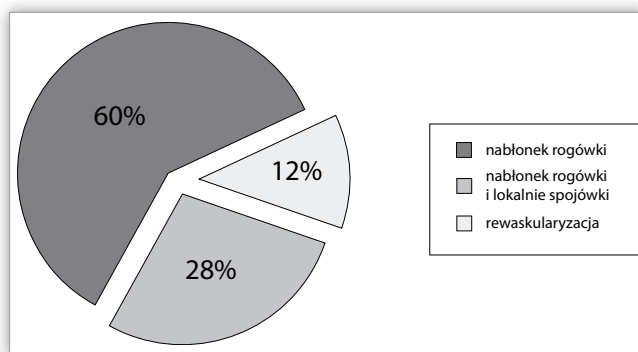


Fig. 2. Results of ocular surface reconstruction: present corneal epithelium – 72% of the eyes, failed grafts – 28% of the eyes.

Ryc. 2. Wyniki rekonstrukcji powierzchni oka: obecny nabłonek rogówkowy – 72% oczu, niepowodzenie zabiegu – 28% oczu.

	Patient/ Pacjent	Gender/ age Płeć/ wiek	Burn/ Oparzenie	Grade*/ Stpień	VA° preop/ przed	VA° postop/ po	Neovascularization/ Neowaskularyzacja	Fluorescein staining/ Barwienie fluoresceiną
1.	MP	M/20	thermal	IV	5/25	5/8	none	none
2.	JB	M/37	chemical	V	2/50	5/25	none	none
3.	FB	F/73	chemical	IV	5/50	5/12	none	none
4.	IM	M/44	chemical	V	1/50	5/50	conjunctival	none
5.	MS	M/33	chemical	V	2/50	5/16	none	none
6.	DW	M/43	chemical	V	1/50	5/50	conjunctival	none
7.	MB	F/42	chemical	IV	3/30	5/16	none	none
8.	RM	M/30	chemical	VI	cf	1/50	stromal	present
9.	JF	M/26	chemical	V	1/50	3/50	none	none
10.	TB	M/54	chemical	VI	hm	1/50	stromal	present
11.	MS	M/54	chemical	VI	hm	hm	stromal	present
12.	KR	M/28	chemical	V	cf	2/50	conjunctival	none
13.	MM	M/21	chemical	V	1/50	5/25	none	none
14.	PK	M/29	chemical	V	1/50	5/12	none	none
15.	SŁ	M/34	chemical	VI	hm	1/50	conjunctival	present
16.	DK	M/49	chemical	V	1/50	5/50	none	none
17.	WS	M/68	chemical	VI	hm	1/50	conjunctival	present
18.	DW	M/13	chemical	VI	hm	3/50	local stromal	none
19.	MW	M/23	chemical	V	1/50	5/50	none	none
20.	MS	M/18	chemical	V	1/50	5/25	none	none
21.	MW	M/30	chemical	V	hm	hm	stromal	present
22.	RS	M/41	chemical	IV	3/50	5/10	none	none
23.	JG	M/44	chemical	IV	1/50	5/50	none	none
24.	SW	M/46	chemical	V	1/50	5/25	none	none
25.	WB	M/69	chemical	V	1/50	1/50	stromal	present

*Burn grade evaluation according to Dua scale/ stopień oparzenia wg skali Dua

°VA expressed on Snellen charts/ ostrość na tablicach Snellena

Tab. III. Pre- and postoperative ocular status in investigative group.

Tab. III. Porównanie przed- i pooperacyjnego stanu powierzchni oka u badanych pacjentów.

Discussion

Limbal stem cell deficit as a ocular surface pathology is not so common in general ophthalmic practice. Primary limbal stem cell deficiency is rare and difficult to treat due to bilateral appearance and additional ocular diseases. Nowadays patients suffering from aniridia, epidermal dysplasia, KID syndrome are looking forward to oral mucosa epithelial cultures – a new potential approach in congenital and acquired bilateral pathologies. The latest discoveries showed that this method can be as effective as corneal epithelial cultures (6). Its alternative approach seems to be the solution to failed autologous and allogenic epithelial grafts.

Acquired limbal insufficiency in one eye gives the opportunity to perform autologous cultivated corneal epithelial trans-

plantations. Shimazaki et al. showed that allogenic cultivated epithelium applied in such cases results in a high number of serious complications: persistent epithelial defects, ulcers and perforations (7). They point out, that severe lesion of ocular surface increases failure risk and leads to poor visual outcome. Conjunctival pannus should be superficial or include minimal stromal involvement. Good indication for surgery is lack or minimal stromal vascularization. Deep vessels spread in the stroma suggest a severe burn history and the risk of inadequate inflammatory response after the transplantation. In an eye with present stromal vessels we observed their further extension within the stroma despite antiinflammatory treatment (8,9). It happened despite the stromal keratectomy performed to remove the vascularized tissue. Limbal ischemia and uncon-

trolled revascularization was observed in the eyes with grade V or VI of ocular surface involvement (10). Present conjunctival inferior and superior fornix is important for proper lubrication of the surface and sufficient topical drug delivery. Involvement of the conjunctiva with synechiae decreased the success rate. In general stabilization of the corneal surface after the burn must be confirmed before the procedure – present inflammation or cicatrization leads to a graft failure. It is clear that all the mentioned elements of the ocular surface must be evaluated during qualification. In our material the patients with high grades of ocular surface involvement more frequently developed neovascular complications. Also visual outcomes were much worse if compared to mild cases.

Before the introduction of culture methods, good treatment results of LSCD were achieved in amniotic membrane application combined with conjunctival pannus removal. Meta analysis of such procedures shows satisfactory results mostly in partial LSCD with the maintained corneal epithelial phenotype in 57% of the cases (11). Amniotic membrane application is still a method of choice in acute period of ocular burns to protect as much as possible of the limbal area.

An important prognostic factor is an area of limbal involvement. According to Paulkin et al. results corneal surface restoration can be achieved in 83.3% of the eyes with partial limbal deficiency and in 63.3% total limbal involvement (12). Also our results show that the number of failures increases with the grade of the ocular burn. Stromal and conjunctival revascularization was characteristic for grade V or VI and much less common in lower grades.

Rama et al. observed the eyes after cultivated epithelium transplantation for 10 years. The success rate was 76.6%, epithelial renewal was maintained. However, he also showed that a graft failure is quite common in severe cases. The final success is connected with the type and severity of the ocular damage and postoperative complications (13). Visual acuity also strongly depends on ocular surface status. Good outcomes were observed in grade IV and V. Burns usually affected corneal stroma leading to subepithelial cicatrization. The cultivated epithelia do not make the corneal surface regular, that causes low vision despite a surgical success. The solution in such cases seems to be a subsequent lamellar keratoplasty to treat corneal surface cicatricial irregularities.

Nakamura et al. describe different applications of cultivated epithelium. It can be effective both in chemical injuries as well as in Stevens–Johnson syndrome or ocular pemphigoid (14). However success of these cases seems to be limited by inflammatory reactions and autoaggressive components of the disease. Results of Shimazaki et al. show, that we should be very careful in these cases (7).

Our results show that careful qualification and examination before the surgery can protect patients from a graft failure. The presented data increase value of Dua ocular involvement scale in evaluation of the patients before limbal transplantation. The scale allows precise recipient evaluation resulting in a better surgical approach in particular cases.

In our work we focused on corneal surface restoration, however several patients after ocular burns developed stromal haze. These patients are observed for subsequent need of a la-

mellar or penetrating keratoplasty. Short postoperative period does not allow to establish the number of required additional procedures to improve transparency of the cornea.

Application of animal-derived products (fetal bovine serum – FBS, murine 3T3 fibroblast) is widely discussed. Risk of xenogenetic microchimerism or disease transmission is considered as low, however it must be included in a patient's agreement before the procedure. Bovine serum can be eliminated by available serum-free media or autologous serum in particular cases (15). Advantages of 3T3 coculture are still over the fibroblast-free media if we consider cellular and proliferative capacity of the culture (16).

Acknowledgments

Paper supported by scientific grant of Polish Ministry of Science: N403 067 31/3216.

Bioethical Commission of Silesian Medical University agreement number NN-6501-184/1/05/06

References:

1. Dua HS, Saini JS, Azuara-Blanco A, Gupta P: *Limbal stem cell deficiency: concept, aetiology, clinical presentation, diagnosis and management*. Indian J Ophthalmol 2000, 48, 83-92.
2. Tsubota K, Toda I, Saito H, Shinozaki N, Shimazaki J: *Reconstruction of the corneal epithelium by limbal allograft transplantation for severe ocular surface disorders*. Ophthalmology 1995, 102, 1486-1496.
3. Wagoner MD: *Chemical injuries of the eye: current concepts in pathophysiology and therapy*. Surv Ophthalmol. 1997, 41, 275-313.
4. Roper-Hall MJ: *Thermal and chemical burns*. Trans Ophthalmol Soc UK 1965, 85, 631-653.
5. Dua HS, King AJ, Joseph A: *A new classification of ocular surface Burns*. Br J Ophthalmol 2001, 85, 1379-1383.
6. Inatomi T, Nakamura T, Koizumi N, Sotozono C, Yokoi N, Kinoshita S: *Midterm results on ocular surface reconstruction using cultivated autologous oral mucosal epithelial transplantation*. Am J Ophthalmol. 2006, 141, 267-275.
7. Shimazaki J, Aiba M, Goto E, Kato N, Shimmura S, Tsubota K: *Transplantation of human limbal epithelium cultivated on amniotic membrane for the treatment of severe ocular surface disorders*. Ophthalmology 2002, 109, 1285-1290.
8. Shimazaki J, Higa K, Morito F, Dogru M, Kawakita T, Satake Y, Shimmura S, Tsubota K: *Factors influencing outcomes in cultivated limbal epithelial transplantation for chronic cicatricial ocular surface disorders*. Am J Ophthalmol. 2007, 143, 945-953.
9. Lim P, Fuchsluger TA, Jurkunas UV: *Limbal stem cell deficiency and corneal neovascularization*. Semin Ophthalmol. 2009, 24, 139-148.
10. Pauklin M, Steuhl KP, Meller D: *Characterization of the corneal surface in limbal stem cell deficiency and after transplantation of cultivated limbal epithelium*. Ophthalmology. 2009, 116, 1048-1056.
11. Saw WPJ, Minassian D, Dart JKG, Ramsay A, Henderson H, Poniatiowski S, Warwick RM, Cabral S, and the Amniotic Membrane Tissue User Group (AMTUG): *Amniotic membrane transplantation for ocular disease: a review of the first 233 cases from the UK user group*. Br J Ophthalmol 2007, 91, 1042-1047.

12. Pauklin M, Fuchsluger TA, Westekemper H, Steuhl KP, Meller D: *Midterm results of cultivated autologous and allogeneic limbal epithelial transplantation in limbal stem cell deficiency.* Dev Ophthalmol 2010, 45, 57-70.
13. Rama P, Matuska S, Paganoni G, Spinelli A, De Luca M, Pellegrini G: *Limbal stem-cell therapy and long-term corneal regeneration.* N Engl J Med. 2010, 363, 147-155.
14. Nakamura T, Inatomi T, Sotozono C, Ang LP, Koizumi N, Yokoi N, Kinoshita S: *Transplantation of autologous serum-derived cultivated corneal epithelial equivalents for the treatment of severe ocular surface disease.* Ophthalmology. 2006, 113, 1765-1772.
15. Lekhanont K, Choubtum L, Chuck RS, Sangiampornpanit T, Chuckpaiwong V, Vongthongsri A: *A serum- and feeder-free technique of culturing human corneal epithelial stem cells on amniotic membrane.* Mol Vis 2009, 15, 1294-1302.
16. Meyer-Blazejewska EA, Kruse FE, Bitterer K, Meyer C, Hofmann-Rummelt C, Wunsch PH, Schlötzer-Schrehardt U: *Preservation of the limbal stem cell phenotype by appropriate culture techniques.* Invest Ophthalmol Vis Sci 2010, 51, 765-774.

The study was originally received 18.01.2011 (1263)/
Praca wpłynęła do Redakcji 18.01.2011 r. (1263)
Accepted for publication 31.10.2011/
Zakwalifikowano do druku 31.10.2011 r.

Reprint requests to/ Adres do korespondencji:
dr n. med. Dariusz Dobrowolski
Oddział Okulistyczny Okręgowego Szpitala Kolejowego
ul. Panewnicka 65
40-760 Katowice
e-mail: dardobmd@wp.pl



**II Międzynarodowa Konferencja
Okulistyka - kontrowersje
Wrocław – Karpacz**

**20-22 września 2012 r.
Hotel Gołębiewski w Karpaczu**

Organizator:
Katedra i Klinika Okulistyki
Akademii Medycznej we Wrocławiu
50-556 Wrocław, ul. Borowska 213
tel: 71 736 43 00, fax: 71 736 43 09
klinika@okulist.am.wroc.pl
www.okulist.am.wroc.pl

Biuro Organizatora:
InspireCongress
50-315 Wrocław, ul. Nowowiejska 38
tel. 71 780 90 52, faks 71 780 90 54
biuro@inspirecongress.pl
www.inspirecongress.pl



www.okulistyka-kontrowersje.pl